

Clinical, Histologic and Histomorphometric Evaluation of Bone Strip Allograft with Resorbable Membrane in Horizontal Alveolar Ridge Augmentation: A Preliminary Study

¹Babak Amooian ²Maryam Seyyed Majidi ³Mahmoud Haji Ahmadi *⁴Amir Kiakojouri

¹Assistant Professor, Dept. of Periodontics, Dental Materials Research Center, School of Dentistry, Babol University of Medical Sciences, Babol, Iran.

²Associate Professor, Dept. of Oral & Maxillofacial Pathology, Dental Materials Research Center, School of Dentistry, Babol University of Medical Sciences, Babol, Iran.

³Assistant Professor, Dept. of Biostatistics & Epidemiology, Infectious Diseases & Tropical Medicine research Center, School of Medicine, Babol University, Babol, Iran.

*⁴Assistant Professor, Dept. of Periodontics, Dental Materials Research Center, Dental School, Babol University of Medical Sciences, Babol, Iran. E-mail: am.kiakojori@mubabol.ac.ir

Abstract

Objective: Alveolar ridge preservation in patients with inadequate bone volume is one treatment option for successful implant placement and can be done by using bone graft materials. On the other hand, Ceno Bone has been recently produced by Hamanand Saz Baft Kish Co. as a bone bioimplant of allograft origin. This study aimed to assess the clinical, histologic and histomorphometric results of Bone Strip Allograft (CenoBone) for horizontal alveolar ridge augmentation.

Methods: In this semi-experimental clinical trial, 7 areas requiring horizontal ridge augmentation and subsequent implant placement in the maxilla were selected using non-randomized consecutive sampling. Surgeries were mostly performed via the buccal cortical plate of the edentulous ridge. The buccal bone was decorticated, Ceno Bone was fixed by titanium screws, covered with Ceno Membrane (resorbable) and sutured. Buccolingual width of the ridge was measured in stage-one surgery and six months later in stage-two surgery for implant placement. A core biopsy was also taken to assess the trabecular thickness, percentage of new bone formation, percentage of remnant particles, degree of inflammation, foreign body reaction, vitality, bone-biomaterial contact and number of blood vessels by microscopic, histologic and histomorphometric analyses of the slides. The clinical ridge width values in the first- and second-stage surgeries were analyzed using Wilcoxon Signed Rank test.

Results: The mean clinical ridge width at 2mm distance from the ridge crest was 2.49 (0.72) mm in the first-stage and 4.79 (0.75) mm in the second-stage surgery. The mean clinical ridge width at 5mm distance from the ridge crest was 3.6 (0.57) mm in the first-stage and 6.3 (1.13) mm in the second-stage surgery. At both sites, application of Ceno Bone significantly increased the clinical ridge width in the second-stage surgery (both $p < 0.05$). Also, inflammation in most specimens (85.7%) was grade I and no case of foreign body reaction was seen. Bone was vital in all patients. The mean trabecular thickness was 87.96 (38.74) μ . The percentage of new bone formation was 58.43 (26.42%) and the percentage of remnant particles was 4.07% (2.44%).

Conclusion: The results of this preliminary study revealed that application of CenoBone stimulates osteogenesis and significantly increases the clinical ridge width at 2 and 5mm distances from the ridge crest for implant placement.

Key words: Ceno Bone, Clinical, Horizontal augmentation, Osteogenesis, Ridge, Width.

Please cite this article as follows:

Amooian B, Seyyed Majidi M, Haji Ahmadi M, Kiakojouri A. Clinical, Histologic and Histomorphometric Evaluation of Bone Strip Allograft with Resorbable Membrane in Horizontal Alveolar Ridge Augmentation: A Preliminary Study. J Dent Sch 2014; 32(2): 80-89.

Received: 03.06.2013

Final Revision: 26.01.2014

Accepted: 05.02.2014

Introduction:

Alveolar ridge resorption is a consequence of tooth extraction and is due to the changed physiological state of the bone (1). Six to 12 months after tooth extraction, 0.34-7.7 mm reduction occurs in ridge width and 0.2 to 3.25 mm in ridge height (2). Severe alveolar ridge resorption complicates the placement of conventional bridges or dental implants; and consequently, increases the treatment cost and duration (3). For years, autogenous bone procured from an intraoral or extraoral source was the gold standard for bone grafts. However, problems associated with the second surgery to procure bone, its invasiveness and limited volume of bone that could be taken (from an intraoral source) led to development of new approaches and production of bone replacement materials (4). Several allografts have been produced for this purpose including Freeze-Dried Bone Allograft (FDBA) and Demineralized Freeze-Dried Bone Allograft (DFDBA). Allogeneic products have several surgical applications due to their biocompatibility and bone remodeling potential (5, 6). On the other hand, CenoBone is a biomaterial produced by Hamanand Saz Baft Kish Co. as a bone bioimplant of allograft origin. Graft materials like CenoBone are made of non-vital connective tissue of human origin. After processing, they preserve their extracellular matrix. This matrix acts as a scaffold and re-accumulates the fibroblasts, blood vessels and epithelium from the adjacent host tissues (7). Sarkarat, *et al.* (2010) performed ridge preservation by using Ceno Bone graft material and confirmed its biocompatibility (7). Evidence regarding the use of bone allografts for alveolar ridge augmentation shows positive results. However, due to the existing limitations in this regard, most studies have been conducted on animal models (8). Considering the manufacturing of Ceno Bone by Hamanand Saz

Baft Kish Co., this study aimed to assess the clinical, histologic and histomorphometric results of Bone Strip Allograft (Ceno Bone) for horizontal ridge augmentation.

Methods:

This semi-experimental clinical trial was conducted on 5 patients (3 men and 2 women) presenting to the Periodontology and Implant Department of Babol University of Medical Sciences requiring implant treatment in the anterior and posterior areas of the maxillary edentulous ridge. Dimensions of the edentulous are as were equal to one or two lost teeth. A total of 8 areas were surgically treated in these patients. In all cases, tooth loss was reported to be due to severe caries in the past 1-3 years. Patients were in the age range of 30-60 years and signed written informed consent. The study design was approved by the ethics committee of the Research Deputy of Babol University of Medical Sciences (#5720) and this clinical trial was registered in IRCT (#IRCT 201202251760 N16). All specimens had adequate bone height but inadequate buccolingual width (less than 5mm and minimum of 2mm in clinical measurement of ridge width). Screening measurements were made using 3D Bone Caliper (Blue & Green Co., Canada) over the soft tissue (Figure 1).

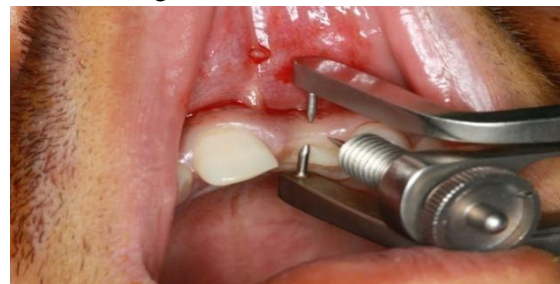

Figure 1- Primary screening measurement of the ridge width with 3D bone caliper

Patients with systemic conditions affecting the healing such as uncontrolled diabetes mellitus, autoimmune disease or local or systemic bone

Horizontal alveolar ridge augmentation 82

conditions, history of alcoholism, substance abuse, current cigarette smoking, pregnancy and taking immunosuppressive or anticoagulants were excluded from the study. Patients with poor cooperation or untreated active periodontal disease and also those who did not pay much attention to oral hygiene practice or were not capable of doing it were excluded from the study. All patients received 2g of amoxicillin half an hour before the surgery and rinsed 0.2% chlorhexidine mouthwash for one minute (8). After local anesthesia with 2% lidocaine, a crestal incision was made by #15 scalpel on the edentulous ridge followed by two vertical releasing incisions at the two ends of the horizontal cut. A full thickness flap was elevated to access buccal cortical plate. Soft tissue was removed from the bone surface and the buccolingual thickness of the ridge was clinically measured at 2-5 mm distances from the bone crest using a 3D bone caliper (Blue & Green Co., Canada). It was vertically adjusted at 2-5 mm distances from the ridge crest with 0.1 mm precision. In order for the measurements to be standard and reproducible, a reference point at a specific distance from the proximal surface of the adjacent tooth was selected by a sliding caliper (Blue & Green, Canada) and all measurements were made at this point by one periodontist and repeated for three times; the mean value was recorded. Before applying the biomaterial, the buccal cortical plate was decorticated using #2 round bur at 4 mm intervals.

Periosteum was released to allow tension-free closure of the flap. The mineralized cortico-cancellous strip, already immersed in saline solution for 30 minutes for rehydration, was fixed to the bone by two titanium screws (CITAGENIX, Canada) in maximum adaptation with the underlying bone (Figure 2).

The bone strip measured 10x20mm; but was cut with a disc if necessary to fit the graft recipient site. Empty spaces around the strip were filled

with mineralized cortico-cancellous powder with 150-1000 μ particles mixed with saline.

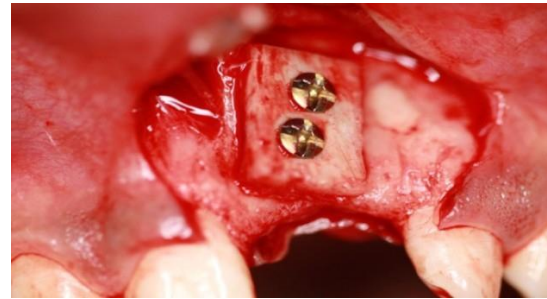

Figure 2- Placement of bone block and fixing it with titanium screws

Ceno Membrane (resorbable) with 0.2-0.6mm thickness (derived from allogeneic pericardium) was placed over the graft materials. Strip, bone powder and resorbable membrane were all purchased from Hamanand Saz Baft Kish Co. The flap was placed over the membrane and fixed tension-free with 5/0 Vicryl mattress and interrupted sutures. Amoxicillin and metronidazole were administered three times a day for 10 days. Analgesics and 0.2% chlorhexidine mouthwash were also administered three times a day for 14 days. The patient was scheduled for suture removal 14 days later (8). Six months after the augmentation, re-entry surgery was performed for placement of implants. A full thickness flap was elevated. Titanium screws were removed and measurements were made at the same sites as in stage-one surgery (Figure 3).

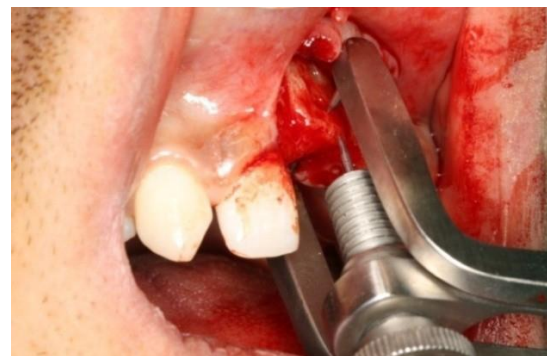


Figure 3- Re-measuring the ridge width at the second-stage surgery

To ensure that the teeth will not be displaced during this time period, an impression was made from the area before the stage-one surgery. The obtained cast was compared with the clinical situation at the second-stage surgery and confirmed no tooth displacement. A biopsy core was obtained by a 3mm Trephine bur from the buccal plate of the ridge. The biopsy site was filled with allogeneic bone powder and covered with Ceno Membrane. Implant holes were prepared according to the manufacturer's instructions. Biopsy specimens were immersed in formalin and sent to the laboratory for histologic and histomorphometric analyses.

Obtained biopsies were stored in 10% formalin for 10 days for complete fixation. For decalcification, specimens were immersed in 10% formic acid for one week. Specimens were evaluated daily to assess their softness (decalcification to facilitate sectioning by a microtome). Specimens were then removed from formic acid solution and stored in 20% lithium bicarbonate for five minutes to neutralize the acid. Each specimen was coded and vertically sectioned into two halves in an anterior-posterior direction. The sectioned part (representing the middle part of the bone) was stained with India ink and coded according to the specimen code. Serial dehydration was performed using increasing concentrations of ethanol and specimens were embedded into paraffin blocks from the same coded side. Paraffin blocks of each bone specimen were sectioned into seven, 5 μ -thick slides, stained with hematoxylin and eosin (H & E) and assessed by BX41 light microscopy (Olympus, Tokyo, Japan).

Based on the study protocol, histologic and histomorphometric analyses were done on bone specimens. In histopathological assessment, slides were evaluated for: 1. Degree of inflammation, 2. Presence or absence of foreign body reaction (giant cells and granulomatous reaction), 3. Bone vitality (presence or absence of osteocytes in the lacunae) and 4. Bone-

biomaterial contact (presence or absence of connective tissue between bone segments) and these parameters were measured and recorded by a pathologist.

Degree of inflammation was determined using the following grading system (9):

Grade 0: Absence of inflammatory cells

Grade 1: Presence of a few scattered inflammatory cells (mild)

Grade 2: Presence of 5-10 inflammatory cells (focal)

Grade 3: Presence of 10-50 inflammatory cells (focal)

Grade 4: Presence of more than 50 inflammatory cells (severe inflammation)

All sections prepared from each biopsy of the graft area were photographed by a digital camera under BX41 light microscope (Olympus, Tokyo, Japan) at 40X magnification. Images in JPEG format were entered in SIS LS Starter software. Areas of new bone formation were selected and percentage of osteogenesis was calculated based on the ratio of bone area to the entire image area (Figure 4).

In histomorphometric analysis, the trabecular thickness was also measured and classified as follows:

Grade I: More than 60 μ (thick)

Grade II: Between 20-60 μ (moderate)

Grade III: Between 1-20 μ (thin)

Number of blood vessels in three microscopic fields at 10X magnification was also assessed. Less than 3 blood vessels was given a score of 0; 3-5 blood vessels was given a score of 1 and more than 5 blood vessels was given a score of 2 (10). The pathologist was not aware of the biopsy content in any phase of the study to prevent any bias in interpretation of histologic and histomorphometric results. To assess the accuracy of measurements, 7 sections were made of each biopsy and the mean value was reported as the definite result.

Clinical ridge widths at 2 and 5mm distances from the crest in first- and second-stage

Horizontal alveolar ridge augmentation 84

surgeries were statistically analyzed using Wilcoxon Singed Rank test at $p < 0.05$ level of significance (due to limited sample size).

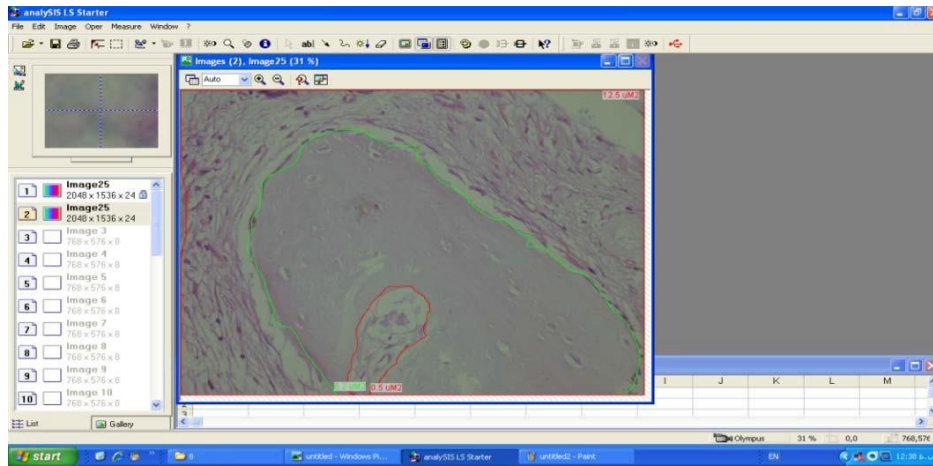


Figure 4- Calculating the percentage of new bone formation in SIS LS Starter software

Results:

This study was conducted on 5 patients (3 males and 2 females) with a mean age of 41.6 years (range 35-46) who were candidates for dental implant treatment. Blocks were surgically placed in 8 areas. In the second-phase surgery, one block failed and the remaining 7 were statistically analyzed. The mean trabecular

thickness was 87.96 (38.74 μ) (grade I) (range 140.31 (18.41 μ)). The mean percentage of new bone formation was 58.43% (26.42%) (range 90.88- 14.14%). The mean percentage of remnant particles was 4.07 (2.44%) (range 0.56- 8.19%).

Histological findings in each slide are summarized in Table 1.

Table 1- Histological findings of biopsy specimens in terms of inflammation, foreign body reaction, vitality, newly formed bone-biomaterial contact and number of blood vessels

Number of specimen	Degree of inflammation	Foreign body reaction	Vitality	Bone-biomaterial contact	Blood vessel
1	1	-	+	-	0
2	1	-	+	+	0
3	1	-	+	+	1
4	1	-	+	+	2
5	4	-	+	+	0
6	1	-	+	-	1
7	1	-	+	*-	2

According to Table 1, degree of inflammation was grade 1 in 6 cases (85.7%) and grade 4 in one case (14.3%). Foreign body reaction was not seen in any case. Bone in all specimens was vital (positive vitality). The newly formed bone-biomaterial contact was in the form of connective tissue in 3 cases (42.9%) and direct

contact in 4 cases (57.1%). In terms of the number of blood vessels, 3 (42.9%) cases had grade zero (blood vessels less than 3), 2 cases (28.6%) had grade 1 (3-5 blood vessels) and 2 cases (28.6%) had grade 2 (over 5 blood vessels) (Figures 5-7).

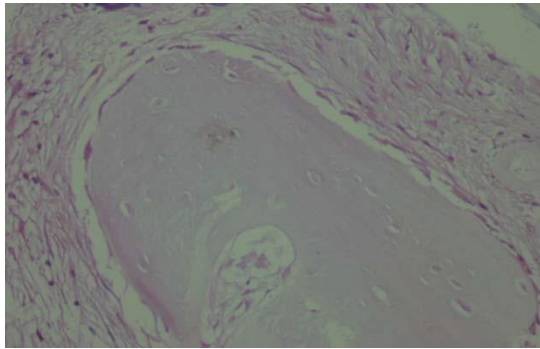


Figure 5- Newly formed bone (bone vitality and osteocytes in the lacunae)(H & E staining at 40X magnification)

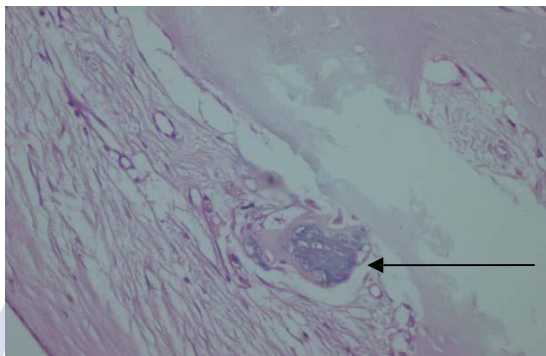


Figure 6- Remnant particles (direct contact of biomaterial with the newly formed bone)(H & E staining at 40X magnification)

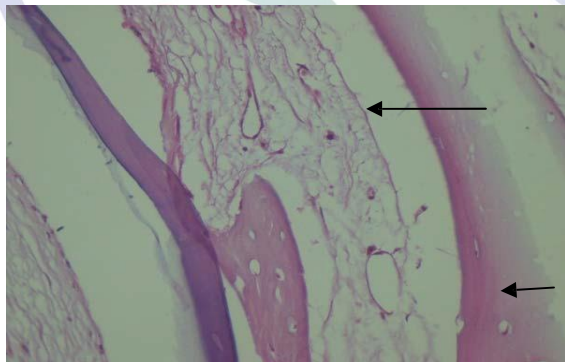


Figure 7- Newly formed vessels in bone graft (H & E staining at 10X magnification)

The mean (SD) clinical ridge width at 2mm distance was 2.49 (0.72) mm in the first-stage surgery and 4.79 (0.75) mm in the second-stage surgery. Wilcoxon Signed Rank test demonstrated that the clinical ridge widths after the application of Ceno Bone significantly increased in the second-stage surgery ($p=0.003$). Also, the mean (SD) clinical ridge width at 5mm

distance was 3.6 (0.57) mm in the first-stage surgery and 6.3 (1.13) mm in the second-stage surgery. Wilcoxon Signed Rank test demonstrated that the clinical ridge widths after the application of Ceno Bone significantly increased in the second-stage surgery ($p=0.003$).

Discussion:

This study aimed to assess the clinical, histologic and histomorphometric results of Ceno Bone (bone strip allograft) for horizontal alveolar ridge augmentation. Based on the results, the mean (SD) clinical ridge width at 2mm distance was 2.49 (0.72) mm in the first-stage surgery and 4.79 (0.75) mm in the second-stage surgery. The clinical ridge widths after the application of Ceno Bone significantly increased in the second-stage surgery (mean increase in width of 2.3 mm, range: 0.9-3.3 mm). Also, the mean (SD) clinical ridge width at 5mm distance was 3.6 (0.57) mm in the first-stage surgery and 6.3 (1.13) mm in the second-stage surgery. The clinical ridge widths after the application of Ceno Bone significantly increased in the second-stage surgery (mean increase in width of 2.7 mm, range: 1.8-4 mm). Therefore, Ceno Bone induced osteogenesis and significantly increased the clinical ridge width at 2 and 5mm distances from the crest. Toscano, *et al.* (2010) retrospectively evaluated the outcome of horizontal ridge augmentation using DFDBA, spongy bone chips and thermoplastic carrier along with collagen membrane and reported 3.5mm increase (range 3-6mm) in horizontal ridge width (11). Also, Geurs, *et al.* (2008) evaluated the efficacy of polyglycolic acid/trimethylene carbonate (PGA/TMC) barrier membrane with longer absorption time combined with demineralized bone matrix and cortical cancellous chips dispersed in a thermoplastic biologic carrier and showed that the mean ridge width at the crest increased from 2.4 to 5.2 mm and the mean width 4 mm apical

to the crest increased from 4.4 to 7.5mm. This finding indicated that allograft in conjunction with PGA/TMC membrane caused significant horizontal alveolar ridge augmentation (12).

Sarkarat, *et al.* (2010) evaluated the effects of Ceno Bone (Hamanand Saz Baft Kish) and OSSEO+ (allograft, IMTEC, USA) and demonstrated that both materials had relatively similar efficacy for preserving the width and height of the alveolar ridge (7). This finding confirms our study results regarding the osteoinductive properties of Ceno Bone.

It has been demonstrated that allogeneic graft materials can replace autografts in bone augmentation procedures (4). Peleg, *et al.* (2010) used cortico-cancellous allogeneic bone blocks for augmentation of alveolar bone defects and reported that using this graft combined with guided bone regeneration (GBR) can be a valuable alternative to autogenous graft in patients with alveolar ridge defects (13).

Procuring an autograft traumatizes the patient and finding an alternative with similar healing ability can greatly help both patients and clinicians (14). In this study, Ceno Bone allograft was used for osteogenesis and increasing the clinical width of the ridge for implant treatment.

Bone graft material must be able to induce significant osteogenesis. Review of the literature reveals that most of the currently available bone graft materials are capable of 14-44% new bone formation (15). Cammak, *et al.* (2005) histologically assessed mineralized and demineralized freeze-dried bone allografts for ridge and sinus augmentations and reported the mean percentage of new bone formation to be 41.89% in the FDBA and 41.74% in the DFDBA group (16). Strietzel, *et al.* (2007) evaluated the clinical and histological results of lateral alveolar ridge augmentation using a synthetic nano-crystalline hydroxyapatite bone substitution material (Ostim) and reported that the mean percentage of areas of bone colonizing

the defect was 52.3% (17). In our study, the mean percentage of bone formation following the application of Ceno Bone was 58.44% (range 14.14-90.88%); which is higher than the rates reported in previous studies. Thus, it appears that application of Ceno Bone can greatly enhance osteogenesis. Wood and Mealey (2012) emphasized the use of mineralized and demineralized freeze-dried bone allografts and reported that DFDBA significantly increased the percentage of vital bone compared to FDBA (38.42% versus 24.63%). FDBA is an osteoconductive and DFDBA is an osteoinductive graft material. According to in-vitro studies, DFDBA has greater osteogenic potential than FDBA; thus, its application is preferred (18). In our study, FDBA cortico-cancellous strip bone block was used due to its superior manipulation ability and also its stability (no breakage) during surgery when screw fixing. DFDBA blocks made by Hamanand Saz BaftKish Co. are of cancellous type and thus, could not be used in the clinical setting of our study due to the mentioned reason. The osteoinductive properties of the graft materials depend on the age of donor (19), and the preparation process in the tissue bank (20). Schwartz, *et al.* (1998) emphasized that FDBA must be procured from donors younger than 50 years of age and the best age for a graft donor is younger than 29 years (19). The catalog of the Hamanand Saz Baft Kish Co. does not reveal any information about the exact age of donors but it has been stated that most donors are young.

The preparation method of graft material also plays an important role in its osteoinductive properties (20). According to the CenoBone manufacturer, all phases of procurement and processing of graft materials are conducted according to the FDA standards and UK codes of conduct for the production of human-derived therapeutic products.

Based on the results, inflammation in the

majority of specimens (85.7%) was grade 1 and grade 4 was only observed in one case (14.3%). Also, no case of foreign body reaction occurred. All specimens were vital. In terms of bone-biomaterial contact, 57.1% showed direct contact and connective tissue was seen in 42.9%. Also, in 42.9% of the slides, number of blood vessels was less than 3, in 28.6% between 3-5 and in 28.6% over 5. Considering the vitality of newly formed bone, it appears that Ceno Bone acts as a scaffold for normal osteoinduction; which is in accord with the results of Sarkarat, *et al.*, about this material (2010)(7).

Histomorphometric analysis of microscopic slides, despite some advantages, provides a 2D image of a 3D space and causes some limitations in interpretation of histological sections of bone augmentation sites (21). Thus, in addition to the effects of biological factors on the thickness of bone trabecula, technical issues can also affect the microscopic view and may explain the controversial results. On the other hand, the histomorphometric values reported in different studies must be interpreted with care and compared with caution; because, taking a biopsy is different in animal and human models. Obtaining a biopsy core in human studies is different as well; some are obtained vertically and some horizontally (22). In this study, the mean percentage of remnant particles was $4.07\% \pm 2.44\%$ (range 0.56%-8.19%). In a study by Toloue, *et al.* (2012) the mean percentage of remnants following the application of calcium sulfate with freeze-dried bone allograft was found to be 2.5%; which is in accord with the current results (22). In a study by Wood and Mealey (2012) using mineralized and demineralized freeze-dried bone allograft, DFDBA group showed a significantly lower mean percentage of remnant particles (8.88% versus 25.42%); both these values were higher than our obtained amounts (18).

The material used as protective membrane barrier in GBR must have characteristics like

biocompatibility, preventing the migration of cells from the host adjacent tissue, the ability to maintain the space and easy clinical application. One drawback of using resorbable membranes is the limited control over the membrane resorption time. Usually, a membrane must be able to maintain its integrity for more than 6 months. However, most membranes are quickly disintegrated by enzymes released from macrophages and neutrophils after placement in the tissue and rapidly lose their integrity (23). In the current study, pericardium resorbable allogeneic membrane with 0.2-0.6mm thickness was used. The reason is, at the time, non-resorbable membranes were not available in the Iranian dental market and due to financial problems, the authors could not obtain them from elsewhere. However, use of a non-resorbable membrane is recommended in future studies to ensure that soft tissue does not interfere with the process of GBR.

One advantage of the current study is that it was a clinical trial conducted on humans. Therefore, the results can be generalized to other clinical settings.

In our study, one failure occurred in the second-phase surgery. In the mentioned patient, during the re-entry surgery, fibrous tissue was observed in the mesial of bone block over one of the screws. After removing the screws, the block was removed because it was unstable. The reason may be that the bone loss around the screws and formation of fibrous tissue at the site, might have resulted in graft mobility and consequent misfit with the underlying tissue. On the other hand, mal adaptation of the graft with the underlying tissue during application (presence of gap) is also another suggested reason that might have been responsible for this failure.

Conclusion:

Based on the clinical, histologic and

histomorphometric results of this preliminary study, Ceno Bone seems to be a suitable graft material to increase the clinical ridge with and stimulate osteogenesis prior to implant

treatment.

Conflict of Interest: “None Declared”

References:

1. Bartee BK. Extraction site reconstruction for alveolar ridge preservation. Part 1: rationale and materials selection. *J Oral Implantol* 2001; 27: 187-193.
2. Shi B, Zhou Y, Wang YN, Cheng XR. Alveolar ridge preservation prior to implant placement with surgical-grade calcium sulfate and platelet-rich plasma: a pilot study in a canine model. *Int J Oral Maxillofac Implants* 2007; 22: 656-665.
3. Schmidlin PR, Jung RE, Schug J. Prevention of alveolar ridge resorption after tooth extraction- a review. *Schweiz Monatsschr Zahnmed* 2004; 114: 328-336.
4. Jensen SS, Broggin N, Hjørting-Hansen E, Schenk R, Buser D. Bone healing and graft resorption of autograft, anorganic bovine bone and Beta-tricalcium phosphate. A histologic and histomorphometric study in the mandibles of minipigs. *Clin Oral Implants Res* 2006; 17: 237-243.
5. Lindhe J, Lang NP, Karring T. *Clinical Periodontology and Implant Dentistry*. 5th Ed. Blackwell Publishing Ltd 2008; Chap 25: 551-552.
6. Urist MR, Strates BS. Bone formation in implants of partially and wholly demineralized bone matrix including observations on acetone-fixed intra and extracellular proteins. *Clin Orthop Relat Res* 1970; 71: 271-278.
7. Sarkarat F, Sadri D, Bohlooli B, Lozani S. Ridge preservation with OSSEO+ compared to Cenobone for implant site development: a clinical and histologic study in humans. *J Res Dent Sci* 2010; 7: 1-6.
8. Nissan J, Marilena V, Gross O, Mardinger O, Chaushu G. Histomorphometric analysis following augmentation of the anterior atrophic maxilla with cancellous bone block allograft. *Int J Oral Maxillofac Implants* 2012; 27: 84-89.
9. Chaushu G, Vered M, Mardinger O, Nissan J. Histomorphometric analysis after maxillary sinus floor augmentation using cancellous bone-block allograft. *J Periodontol* 2010; 81: 1147-1152.
10. Hasheminia SM, Feizi G, Razavi SM, Feizianfard M, Gutknecht N, Mir M. A comparative study of three treatment methods of direct pulp capping in canine teeth of cats: histologic evaluation. *Lasers Med Sci* 2010; 25: 9-15.
11. Toscano N, Holtzclaw D, Mazor Z, Rosen P, Horowitz R, Toffler M. Horizontal ridge augmentation utilizing a composite graft of demineralized freeze-dried allograft, mineralized cortical cancellous chips, and a biologically degradable thermoplastic carrier combined with a resorbable membrane: a Retrospective evaluation of 73 consecutively treated cases from private practices. *J Oral Implantol* 2010; 36: 467-474.
12. Geurs NC, Korostoff JM, Vassilopoulos PJ, Kang TH, Jeffcoat M, Kellar R, *et al*. Clinical and histologic assessment of lateral alveolar ridge augmentation using a synthetic long-term bioabsorbable membrane and an allograft. *J Periodontol* 2008; 79: 1133-1140.
13. Peleg M, Sawatari Y, Marx RN, Santoro J, Cohen J, Bejarano P, *et al*. Use of corticocancellous allogeneic bone blocks for augmentation of alveolar bone defects. *Int J Oral Maxillofac Implants*

- 2010; 25: 153-162.
14. Mellonig JT, Bowers GM, Bailey RC. Comparison of bone graft materials. Part I. New bone formation with autografts and allografts determined by Strontium – 85. *J Periodontol* 1981; 52: 291-296.
 15. Tadjoeidin ES, de Lange GL, Holzmann PJ, Kulper L, Burger EH. Histological observations on biopsies harvested following sinus floor elevation using a bioactive glass material of narrow size range. *Clin Oral Implants Res* 2000; 11: 334-344.
 16. Cammack GV 2nd, Nevins M, Clem DS 3rd, Hatch JP, Mellonig JT. Histologic evaluation of mineralized and demineralized freeze-dried bone allograft for ridge and sinus augmentations. *Int J Periodontics Restorative Dent* 2005; 25: 231-237.
 17. Strietzel FP, Reichart PA, Graf HL. Lateral alveolar ridge augmentation using a synthetic nanocrystalline hydroxyapatite bone substitution material (Ostim). Preliminary clinical and histological results. *Clin Oral Implants Res* 2007; 18: 743-751.
 18. Wood RA, Mealey BL. Histologic comparison of healing after tooth extraction with ridge preservation using mineralized versus demineralized freeze-dried bone allograft. *J Periodontol* 2012; 83: 329-336.
 19. Schwartz Z, Somers A, Mellonig JT, Carnes DL Jr, Dean DD, Cochran DL, *et al.* Ability of commercial demineralized freeze-dried bone allograft to induce new bone formation is dependent on donor age but not gender. *J Periodontol* 1998; 69: 470-478.
 20. Shigeyama Y, D'Errico JA, Stone R, Somerman MJ. Commercially-prepared allograft material has biological activity in vitro. *J Periodontol* 1995; 66: 478-487.
 21. Nouri Moghehi MH, Mahmoudzadeh Sagheb HR, Heidari Z. Practical methods and specialist vocabulary for histotechnic, steriology and morphometri. 1st Ed. Tehran: Tehran University of Medical Sciences Publishing Co. 2004; Chap 7: 176-179. [Persian]
 22. Toloue SM, Chesnoiu-Matei I, Blanchard SB. A clinical and histomorphometric study of calcium sulfate compared with freeze-dried bone allograft for alveolar ridge preservation. *J Periodontol* 2012; 83: 847-855.
 23. von Arx T, Buser D. Horizontal ridge augmentation using autogenous block grafts and the guided bone regeneration technique with collagen membranes: a clinical study with 42 patients. *Clin Oral Implants Res* 2006; 17: 359-366.